



## FIRST PLACE – CROWDING



Dr. Jasbir Cheema  
Valley View Dental  
Stockton, CA

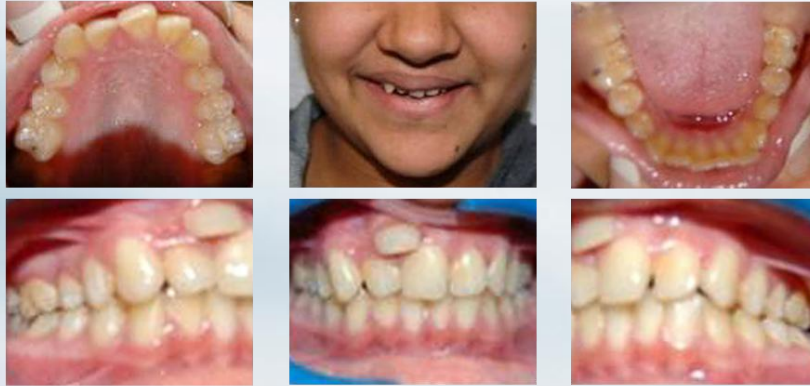

INVISALIGN GALLERY 2011

# FIRST PLACE – CROWDING

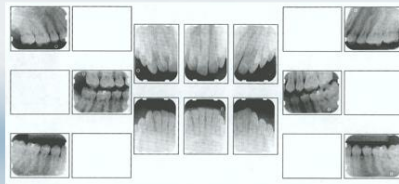


Dr. Jasbir Cheema  
Stockton, CA



BEFORE

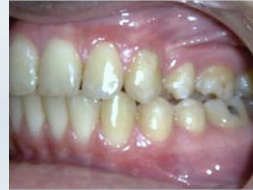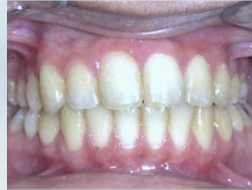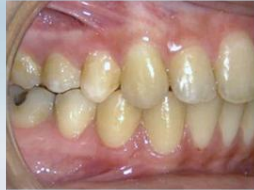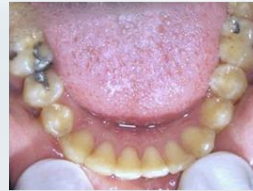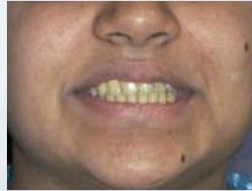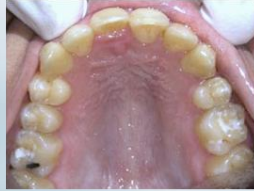Chief Concern:  
Patient had fully  
blocked out central  
incisor (#8) that  
needed to be  
extruded into the  
arch as well.



# FIRST PLACE – CROWDING



Dr. Jasbir Cheema  
Stockton, CA



AFTER

Upper Aligners:  
29 + 33

Lower Aligners:  
29 + 33

Supplemental Tx:  
Interarch elastics,  
buttons/elastics  
(not-interarch)

Retention:  
Vivera retainers